



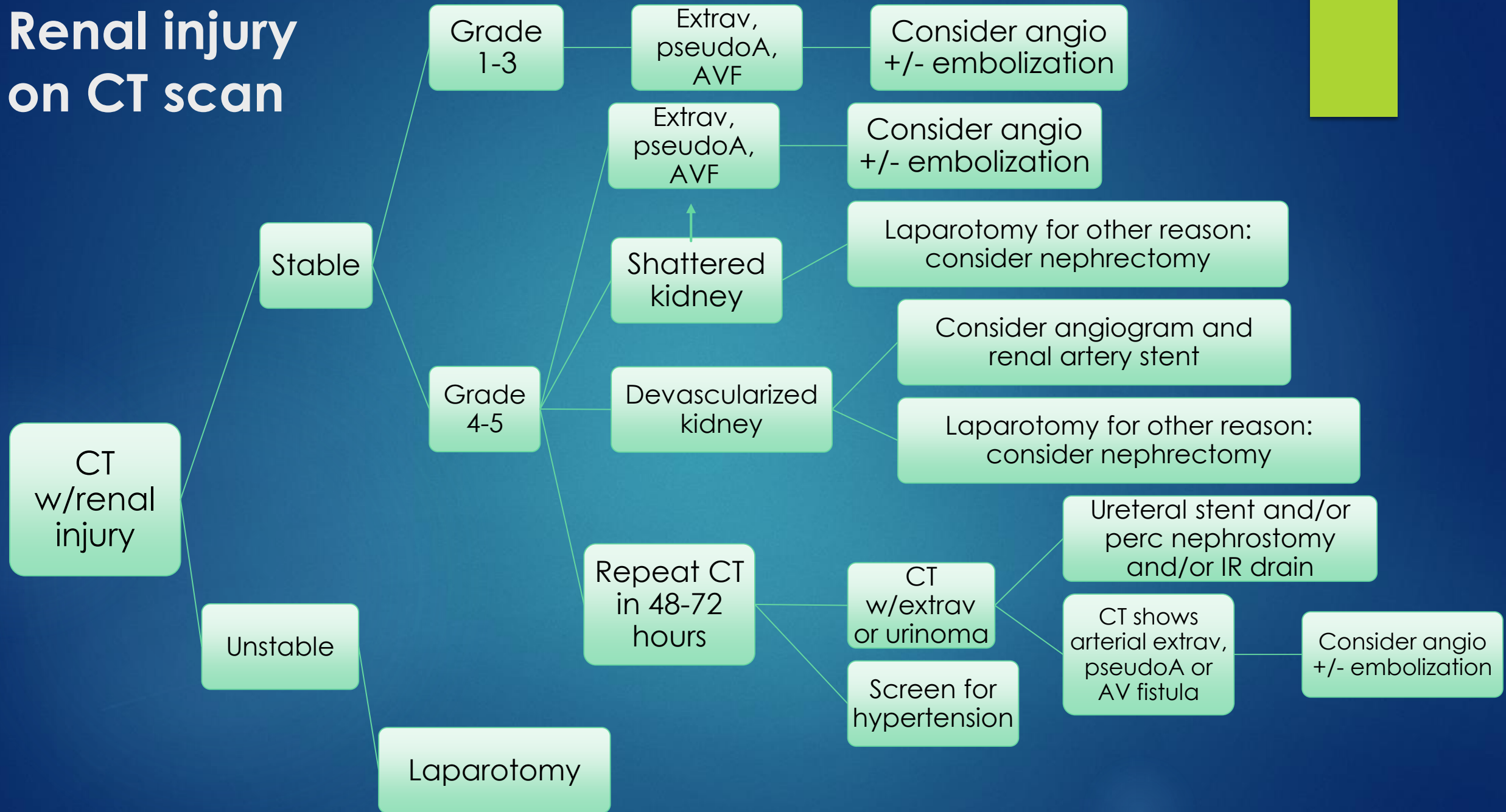
Renal Trauma Management Guideline

REVISED SEPTEMBER, 2020

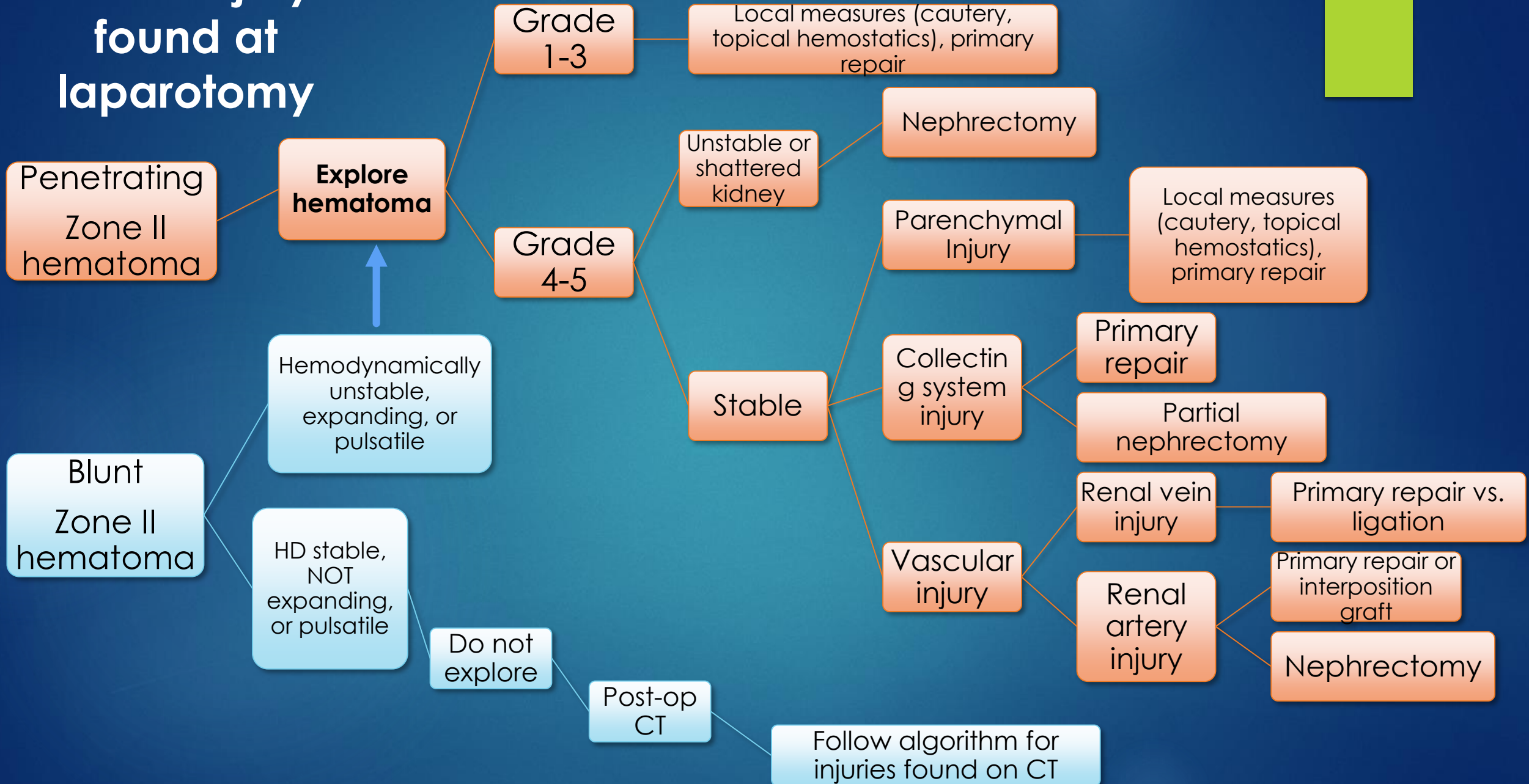
Grading Scale

Grade	Description
1	Contusion: Microscopic or gross hematuria, urologic studies normal Hematoma: Subcapsular, nonexpanding without parenchymal laceration
2	Hematoma: Nonexpanding perirenal hematoma confined to retroperitoneum Laceration: < 1.0 cm parenchymal depth of renal cortex without urinary extravasation
3	Laceration: > 1.0 cm parenchymal depth of renal cortex without collecting system rupture or urinary extravasation
4	Laceration: parenchymal laceration extending through the renal cortex, medulla, and collecting system Vascular: Main renal artery or vein injury with contained hemorrhage
5	Laceration: completely shattered kidney Vascular: Avulsion of renal hilum which devascularizes the kidney

Renal injury on CT scan



Renal injury found at laparotomy



References

- ▶ Brown CVR, Alam HB, Brasel K, et. al. Western Trauma Association Critical Decisions in Trauma: Management of Renal Trauma. J Trauma Acute Care Surg. 2018 Nov;85(5):1021-1025.
- ▶ ATOM/ASSET